

# Visual rehabilitation with scleral contact lenses in patients with irregular astigmatism

## Rehabilitación visual con lentes de contacto escleral en pacientes con astigmatismo irregular

María Alessandra Cano-Blaires <sup>1</sup>, Guillermo Raúl Vera-Duarte <sup>2</sup>, Myriam Blaires <sup>1,3</sup>

<sup>1</sup> Fundación Banco de Ojos, Asunción, Paraguay

<sup>2</sup> Universidad Nacional de Asunción, Hospital de Clínicas, Cátedra de Oftalmología, Asunción, Paraguay

<sup>3</sup> Instituto de Previsión Social, Asunción, Paraguay



Received: 25/10/2023


Revised: 20/12/2023

Accepted: 23/03/2024

### Corresponding author

Guillermo Raúl Vera Duarte  
Universidad Nacional de Asunción,  
Paraguay  
[guillerveraduarte@gmail.com](mailto:guillerveraduarte@gmail.com)

### Responsible editor

Iván Barrios, MSc   
Universidad Nacional de Asunción,  
San Lorenzo, Paraguay.

### Conflicts of interests

The authors declare that there is no conflict of interest.

### Funding

The authors received no financial support for the research, authorship, and/or publication of this article.

This article is published under [Creative Commons Attribution 4.0 International License](https://creativecommons.org/licenses/by/4.0/).



## ABSTRACT

**Introduction:** Scleral contact lenses (SCLs) are gas-permeable and are placed entirely on the sclera without contacting structures such as the cornea or limbus. These ECLs are designed to rehabilitate reduced vision of eyes with irregular corneas. Irregular astigmatism caused by corneal pathologies such as keratoconus, post-transplant, post-refractive surgery, or corneal degeneration produces poor visual acuity that cannot be corrected with air lenses, and the appearance of scleral contact lenses could be a therapeutic option in the treatment and optical correction of corneal pathologies. To determine the degree of improvement in visual acuity with adaptation of scleral lenses. **Methodology:** This was an observational, descriptive, retrospective, cross-sectional, retrospective study. **Results:** Forty cases of irregular astigmatism with different initial visual acuity effects were observed prior to the fitting of Scleral Lenses. The mean visual acuity (VA) prior to correction with scleral lenses observed in the 40 cases was 20/200 with correction on the Snellen scale with a minimum (worst VA) equal to "finger-count vision" (represented as cases with 20/400 vision for quantification purposes) and a maximum (best VA) of 20/70. Nineteen cases (47.5%) restored their VA to normal values (20/20), and 30 cases (75%) improved their VA by at least 10-fold from the baseline. **Discussion:** In this study, a remarkable and constant improvement in visual acuity was observed in all the patients. Some patients experienced an increase of up to 20 times their initial visual acuity, achieving, in many cases, a visual acuity of 20/20 on the Snellen scale. These results indicate a promising treatment strategy with fewer adverse effects.

**Keywords:** Astigmatism; Scleral contact lenses; visual rehabilitation.

## RESUMEN

**Introducción:** Las lentes de contacto esclerales (LCE) son permeables al gas y se colocan totalmente en la esclera sin hacer contacto con estructuras como la córnea o el limbo. Estas LCE son diseñadas para rehabilitar la visión reducida de los ojos con córneas irregulares. Los astigmatismos irregulares producidos por patologías corneales como el queratocono, post trasplante, post cirugía refractiva o degeneraciones corneales producen una mala agudeza visual que no puede ser corregida con lentes aéreas, actualmente con la aparición de las lentes de contacto esclerales podrían ser una de las opciones terapéuticas en el tratamiento y corrección óptica de las patologías corneales. Determinar el grado de mejoría de la agudeza visual con la adaptación de lentes esclerales. **Metodología:** Observacional descriptivo de corte transversal, retrospectivo. **Resultados:** 40 casos de astigmatismo irregular con distintas afectaciones iniciales en la agudeza visual previo a la colocación de las LCE. La media de agudeza visual (AV) previo a la corrección con las lentes esclerales observada en los 40 casos fue de 20/200 con corrección (CC) en la escala de Snellen con un mínimo (peor AV) igual a "visión cuenta dedos" (representado como casos con visión 20/400 con fines de cuantificación) y un máximo (mejor AV) de 20/70. 19 casos (47,5%) restauraron su AV a valores normales (20/20); 30 casos (el 75%) mejoraron su AV al menos 10 veces respecto al valor inicial. **Discusión:** En este estudio, se observó una notable y constante mejora en la agudeza visual de todos los pacientes estudiados. Algunos pacientes experimentaron aumentos de hasta 20 veces su agudeza visual inicial, logrando en muchos casos una agudeza visual de 20/20 en la escala de Snellen. Estos resultados indican un tratamiento prometedor con pocos efectos adversos evidentes.

**Palabras clave:** astigmatismo; lentes de contacto esclerales; rehabilitación visual.

## INTRODUCTION

Astigmatism is a refractive defect of the eye in which there is a different refractive power in different meridians, which prevents a specific image from being formed on the retina from a specific object (1,2). It occurs on a surface whose curvature progresses from a minimum value to a maximum value in perpendicular meridians so that the rays do not suffer the same deviation in all meridians (1). Instead of a single focal point, two focal lines are separated from each other by an interval whose length is directly proportional to the difference in power between the two principal meridians. Irregular astigmatism is caused by corneal pathologies such as keratoconus; post-transplant, post-refractive surgery, or corneal degeneration produce poor visual acuity that cannot be corrected with aerial lenses (3), which could only be corrected with a surgical procedure or simply with the use of special contact lenses (4,5).

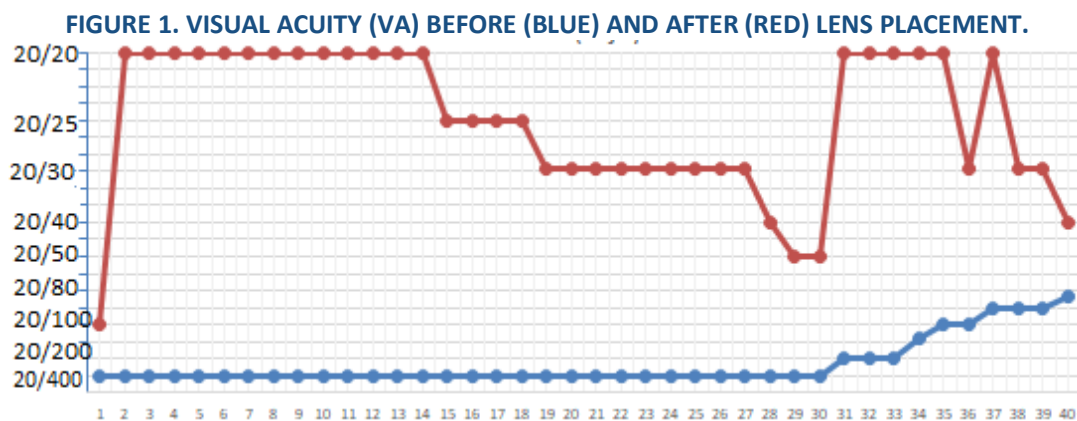
Scleral contact lenses (SCL) are gas permeable and are placed entirely on the sclera without contacting structures, such as the cornea or limbus (6). They are large in size, with diameters that vary between 15 and 20 mm, centering independent of irregularity, a wide optical zone to achieve greater stability of visual acuity in addition to the optical field. One can find formulas that exceed  $\pm 40.00$  diopters. They are designed to locate a thin layer of aqueous liquid above the ocular extension, without allowing air bubbles or foreign bodies to enter the thickness. They are currently manufactured with high oxygen permeability, and there are, for example: Itafloflufocon B Dk 127X10<sup>11</sup>, Equalens II, DK = 110 × 10<sup>11</sup> (7,8). These ECLs are designed to rehabilitate reduced vision in eyes with irregular corneas that are intolerant to rigid contact lenses (7–9). Its reserve fluid functions as a dressing fluid that offers unique therapeutic benefits to the ocular surface. This deposit protects the surface from desiccation and the effects of exposure to air, and acts as a barrier between the cornea and eyelid, significantly reducing the intensity of pain and ocular photophobia, facilitating the healing of persistent epithelial defects, promoting corneal health, and maintaining hydration of the area. Currently, with the appearance of scleral contact lenses, they could be a therapeutic option for the treatment and optical correction of corneal pathologies (10–12) to improve visual acuity (VA) in these patients.

## METHODS

This was a retrospective, cross-sectional, descriptive observational study. This study was conducted in accordance with the standards of the Declaration of Helsinki and its subsequent revisions. No distinction between sex, religion, or politics was made in the inclusion and analysis of the data. Population: Patients diagnosed with irregular astigmatism who could not be fitted with rigid gas-permeable contact lenses within a time frame from March 2019 to March 2021. Non-probabilistic sampling of consecutive cases. Patients of both sexes, of all ages, with a diagnosis of irregular astigmatism who could not be fitted with rigid gas-permeable contact lenses, and who had attended the Fundación Oca del Valle Eye Bank during the research period were included. To calculate the necessary sample size, a prevalence of 2% of patients who could require adaptation of scleral lenses was considered; for a 90% CI and a margin of error of 5%, 20 patients would be required, which would correspond to 40 eyes, for the calculation the Epilinfo 7.2.2.2 statistical package was used. The data were recorded in an Excel 2022 electronic spreadsheet with the variables included in the study and subsequently analyzed using the SPSS program. The results were expressed as frequencies, percentages, means, and standard deviations.

## RESULTS

Forty cases of irregular astigmatism with different initial effects on visual acuity before lens placement. The mean visual acuity (VA) prior to correction with scleral lenses observed in the 40 cases was 20/200 with correction (CC) on the Snellen scale with a minimum (worst VA) equal to “finger-counting vision” (represented as cases with 20/400 vision for quantification purposes), and a maximum (best VA) of 20/70. After scleral lens placement, a mean VA of 20/25 was observed in the study population, with a minimum of 20/100 and a maximum of 20/20. An improvement in the mean VA from the state prior to lens placement of about 13.21 times on average (minimum improvement of 1.78 times and maximum of 20 times) to the post-lens placement state is estimated, considering the total study population. The individual variations in each case are shown in Figure 1. Nineteen cases (47.5%) restored their VA to normal values (20/20), and 30 cases (75%) improved their VA by at least 10 times compared with the initial value.



The mean age of the studied sample was 44.15 years  $\pm$  17 SD, with a median age of 40 years and range from 20 to 84 years. 29 cases corresponding to the male sex and 11 to the female sex were studied. In the female population, the mean age found was 44.9 years  $\pm$  17.1 SD while in the male population it was 43.86 years  $\pm$  17.3 SD. The minimum age for females was 20 years and 22 years for males, with a maximum age of 66 years for females and 84 years for males. Regarding etiologies, 26 cases of keratoconus (65%), 8 postoperative cases of penetrating keratoplasty (20%), 5 postoperative cases of refractive surgery (13%), and 1 case of Terrien's degeneration (2%) were observed. The 40 cases were divided into three groups according to the percentage of VA decrease with respect to the

normal value of 20/20. In the three groups, according to the percentage of VA loss with respect to the normal value of 20/20. The means of the three groups are presented in Table 1, along with the new mean post-placement VA values. It was found that the group with VA loss greater than 90% benefited about 15.76 times on mean compared to the original value, while the group with VA loss between 80% and 90% benefited about 7.425 times compared to the original value, and the group with VA loss between 50 and 79% improved their visual acuity value by a mean of approximately 2.76 times. Complications and their frequencies of occurrence are shown in Table 2.

**TABLE 1. MEAN VALUES OF VISUAL ACUITY (VA) ACCORDING TO THE SNELLEN SCALE BEFORE AND AFTER THE USE OF SCLERAL LENSES (N=40).**

Groups	Pre-Intervention Mean	Post-Intervention Mean
More than 90% (30 cases)	20/400	20/25
Between 80 and 90% (6 cases)	20/140	20/20
Between 50 and 79% (4 cases)	20/70	20/30

**TABLE 2. COMPLICATIONS ASSOCIATED WITH THE USE OF SCLERAL LENSES (N=40)**

Complication	n	%
Muroid deposits in CL (contact lenses)	3	7.5
Perikeratic injection	3	7.5
Red eye	5	12.5
None	29	72.5

## DISCUSSION

The use of LCE for the treatment of corneal irregularities, uncomplicated refractive errors, and ocular surface diseases has increased (11,12). The placement of LCE improved the VA in the 40 cases

studied by a mean of 13.21 times compared to the state prior to adaptation to them and was expressed in values of the Snellen scale, with an mean VA of 20/ 200 to the best mean value of 20/25. Approximately half of the cases had their VA restored to normal values (20/20). Regarding correction values, similar findings

can be observed in the work of Escamilla from 2010 (7) where the majority of patients reached visual acuity values close to 20/50, 20/30 or even 20/20, although this study is focused on those after refractive surgery; In the present study, the cases associated with it were a total of 5. Most cases were derived from keratoconus (13,14), which is consistent with the findings of other studies.

The mean age of the patients who required study intervention was 44.15 years with a standard deviation of 17 years. A normal age distribution was observed. Most patients were male (72%). A similar distribution of ages was found considering each sex separately (mean, median age, and SD in both groups were similar and approximate to that of the population).

Most cases (26 cases, 65%) required the placement of lenses due to keratoconus, followed by other causes, such as postoperative penetrating keratoplasty (PKP) (8 cases, 20%), postoperative refractive surgery (5 cases, 13%), and tertiary degeneration (1 case, 2%).

Most patients (72.5%) did not present with complications after lens application. The most frequently observed complication was red eye (12.5% of the 40 cases), followed by perikeratic injection and mucoid deposits (7.5% each), similar to the reported frequencies (15,16). Depending on the reason for needing the intervention under study, keratoconus cases had a greater probability of developing complications (30.77% of cases). Most episodes of ocular redness were recorded in patients who underwent penetrating keratoplasty. In both sexes, the most frequent complication was absence of complications. However, among the complications reported, in terms of proportion, the most common complication was eye redness, whereas in female patients, the most prevalent complication was the presence of deposited mucoids in the contact lenses.

From a physiological perspective, it has been established that the irregularity of corneal astigmatism in the context of typical human eyes increases as the aging process progresses, but it can also be induced by corneal surface pathologies and ophthalmological surgeries (17–19).

The improvement in VA observed in the present study showed a high and constant value for all patients studied. The finding of an increase of up to 20 times its initial value prior to the application of the lens, and in many cases, the resolution at Snell scale values of 20/20, shows a promising treatment with relatively few adverse effects according to the present findings. In fact, out of every 4 eyes, in 3 of them no type of obvious complications were found at the time of the

post-placement re-evaluation. It will be pertinent to carry out a corresponding follow-up of these patients to evaluate the progression of the pathology that led them to this intervention and the potential presence of complications that may be found. The high number of elevated patients who underwent evaluation, their demographic homogeneity, and the consistent results of improved visual acuity observed are cited as important points. Some points to consider for future work would be to consider a longer follow-up time and the inclusion of additional keratometric tests associated with the state of visual acuity.

## AUTHORS CONTRIBUTIONS

MACB: has contributed to patient monitoring, data collection from patients, and patient follow-up. GRVD: has contributed to patient monitoring, data collection from patients, and patient follow-up. MB: has been the specialist in indicating the treatment to follow and patient follow-up, as well as the handling of obtained data.

## REFERENCIAS

- Gurnani B, Kaur K. Astigmatism. In: StatPearls [Internet]. Treasure Island (FL): StatPearls Publishing; 2023 [cited 2023 Oct 10]. [URL](#)
- Ueno Y, Nomura R, Hiraoka T, Kinoshita K, Ohara M, Oshika T. Comparison of corneal irregular astigmatism by the type of corneal regular astigmatism. *Sci Rep* 2021;11(1):15769. <https://doi.org/10.1038/s41598-021-95358-z>
- Schiefer U, Kraus C, Baumbach P, Ungewiß J, Michels R. Refractive errors. *dtsh Arzteblatt Int* 2016;113(41):693–702. <https://doi.org/10.3238/arztebl.2016.0693>
- Deshmukh R, Ong ZZ, Rampat R, Alió del Barrio JL, Barua A, Ang M, et al. Management of keratoconus: an updated review. *Front Med*. 2023;10. <https://doi.org/10.3389/fmed.2023.1212314>
- Arnalich-Montiel F, Alió del Barrio JL, Alió JL. Corneal surgery in keratoconus: which type, which technique, which outcomes? *Eye Vis*. 2016;3(1):2. <https://doi.org/10.1186/s40662-016-0033-y>
- Harthan JS, Shorter E. Therapeutic uses of scleral contact lenses for ocular surface disease: patient selection and special considerations. *Clin Optom*. 2018;10:65–74. <https://doi.org/10.2147/opto.s144357>
- Quitán AE. Scleral lenses in ectasia and irregular astigmatism after incisional refractive surgery and LASIK. *Cienc Tecnol For Health Vis Ocul*. 2010;8(2):51–61. <http://dx.doi.org/10.19052/sv.822>
- Mariño Hidalgo O, Guerra Almaguer M, Cárdenas Díaz T, Pérez Suárez RG, del Carmen Medina Y, Milanés Camejo R. Scleral lenses: characteristics and indications. *Rev Cuba Oftalmol*. 2017;30(1):0–0. [URL](#)
- Bromley JG, Randleman JB. Treatment strategies for corneal ectasia. *Curr Opin Ophthalmol*. 2010;21(4):255–8. <https://doi.org/10.1097/icu.0b013e32833a8bfe>
- Visser ES, Van der Linden BJ, Otten HM, Van der Lelij A, Visser R. Medical applications and outcomes of bitangential scleral

- lenses. *Optom Vis Sci Off Publ Am Acad Optom.* 2013;90(10):1078–85.  
<https://doi.org/10.1097/OPX.000000000000018>
11. Shorter E, Harthan J, Nau CB, Nau A, Barr JT, Hodge DO, et al. Scleral Lenses in the Management of Corneal Irregularity and Ocular Surface Disease. *Eye Contact Lenses.* 2018;44(6):372–8. <http://dx.doi.org/10.1097/ICL.0000000000000436>
  12. Pullum KW, Whiting MA, Buckley RJ. Scleral contact lenses: the expanding role. *Cornea.* 2005;24(3):269–77. <http://dx.doi.org/10.1097/01.ICO.0000148311.94180.6b>
  13. Lee KE, Moon SY, Nam S, Jang JH, Kim JY, Tchah H, et al. Scleral Lens Applications Focused on Korean Patients with Various Corneal Disorders. *Korean J Ophthalmol KJO.* 2023;37(2):157–65. <http://dx.doi.org/10.3341/kjo.2022.0164>
  14. Ozek D, Kemer OE, Altıaylık P. Visual performance of scleral lenses and their impact on quality of life in patients with irregular corneas. *Arq Bras Oftalmol.* 2018;81(6):475–80. <http://dx.doi.org/10.5935/0004-2749.20180089>
  15. Walker MK, Bergmanson JP, Miller WL, Marsack JD, Johnson LA. Complications and fitting challenges associated with scleral contact lenses: A review. *Contact Lens Anterior Eye J Br Contact Lens Assoc.* 2016;39(2):88–96. <http://dx.doi.org/10.1016/j.clae.2015.08.003>
  16. Ibrahim NK, Seraj H, Khan R, Baabdullah M, Reda L. Prevalence, habits and outcomes of using contact lenses among medical students. *Pak J Med Sci.* 2018;34(6):1429–34. <http://dx.doi.org/10.12669/pjms.346.16260>
  17. Oshika T, Klyce SD, Applegate RA, Howland HC. Changes in corneal wavefront aberrations with aging. *Invest Ophthalmol Vis Sci.* 1999 Jun;40(7):1351–5. [URL](http://dx.doi.org/10.1016/j.ajo.2020.09.045)
  18. Oie Y, Yasukura Y, Nishida N, Koh S, Kawasaki R, Maeda N, et al. Fourier Analysis on Regular and Irregular Astigmatism of Anterior and Posterior Corneal Surfaces in Fuchs Endothelial Corneal Dystrophy. *Am J Ophthalmol.* 2021;223:33–41. <http://dx.doi.org/10.1016/j.ajo.2020.09.045>
  19. Kemraz D, Cheng XY, Shao X, Zhou KJ, Pan AP, Lu F, et al. Age-Related Changes in Corneal Spherical Aberration. *J Refract Surg Thorofare NJ* 1995. 2018;34(11):760–7. <http://dx.doi.org/10.3928/1081597x-20181011-01>